

Enlarged Adenoid in Adult Mimicking Nasopharyngeal Growth

Iqbal Hussain Udaipurwala¹, Muhammad Moiz Ullah Khan²

ABSTRACT

Background: Adenoid hypertrophy is more common in children than in adults, though it may persist into adulthood. Due to its subtle and nonspecific symptoms, it is often overlooked and easily misdiagnosed.

Case Presentation: A 26-year-old male resident of a remote village in Balochistan presented with complaints of nasal obstruction, snoring, and earache, without any complication

like epistaxis or cranial nerve involvement. Nasal endoscopy showed nasopharyngeal mass and imaging demonstrated a soft tissue lesion with isodense. The patient underwent an adenoidectomy and the histopathological diagnosis of the excised tissue was of adenoid hypertrophy.

Conclusion: This case illustrates the consideration of adenoid hypertrophy for the differential diagnosis of adult nasal symptoms to achieve proper treatment with symptom resolution.

Keywords: Adenoidectomy, Adult nasal obstruction, Differential diagnosis, Earache, Nasal endoscopy, Snoring

INTRODUCTION

Lymphoid tissue develops to form adenoids at the back of the nose or on the nasopharynx's posterosuperior wall, which is a crucial component of Waldeyer's Ring. It seems to play a significant part in establishment of what is known as "immunological memory" in younger children¹. Adenoid Hypertrophy usually indicates the non-physiological enlargement of nasopharyngeal tonsils commonly seen in age group of 6 to 10 years and commonly atrophied till 16 years of age². Symptoms of adenoid hypertrophy include obstructive sleep apnea, mouth-breathing, snoring, hyponasal speech and rhinorrhea³. The clinical history, nasopharyngoscopy, and lateral soft X-ray of the nasopharynx are generally used to evaluate adenoid hypertrophy⁴. According to some authors, adenoid hypertrophy in adults is predisposed to by chronic infection, allergic rhinitis, cancer, human immunodeficiency virus (HIV) infection, and smoking⁵. However, the presentation of adenoid hypertrophy in adult and old age group is relatively very uncommon and, in many cases, can be misdiagnosed⁴. In this case report we describe an unusual presentation of nasopharyngeal mass in adult which after definitive investigation and management came out to be adult hypertrophy in adult.

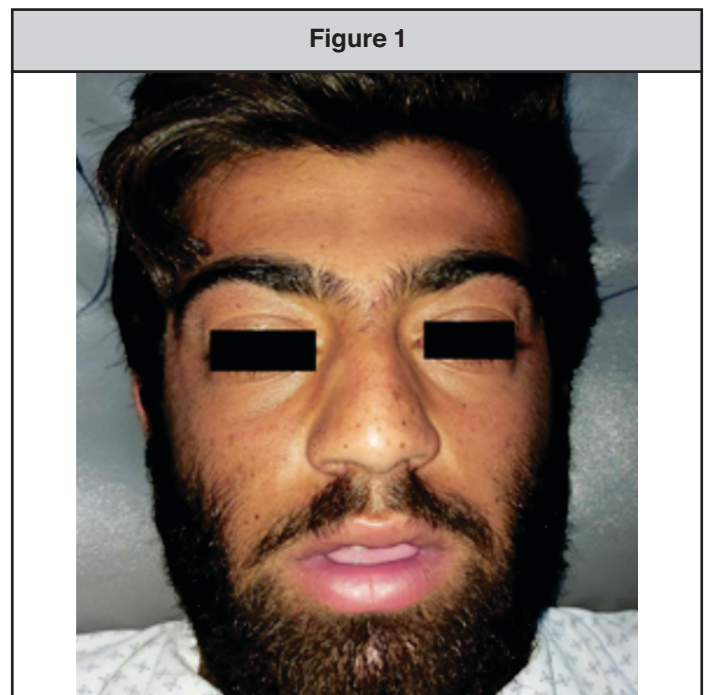
CASE REPORT

"A 26-year-old male presented to the otorhinolaryngology department at a private hospital from a remote village in Balochistan with a history of gradual, progressive, recurrent nasal obstruction, mouth breathing, anterior nasal discharge, snoring, and earache". He had no history of nasal bleeding, Trigeminal Nerve involvement and weight loss. There was no history of pain and fever. The symptoms aggravated with time and didn't get relieve with decongestants. He had not sustained any trauma.

On examination, a young man of average built with stable vital signs and unremarkable systemic examination. Nasal

examination showed no gross external deformity or scar mark. Paranasal sinuses were non tender (**Figure 1**). He had decreased patency and compromised olfactory function. Anterior rhinoscopy was unremarkable. On posterior rhinoscopy there was a mass seen in nasopharynx. Flexible Nasal endoscopic examination showed enlarged soft tissue mass in nasopharynx obstructing the choanae (**Figure 2**). Ophthalmic examination was normal. Neck lymph nodes were not palpable. All base line investigations were within normal limits. X-Ray lateral view was done which showed enlarged soft tissue shadow at base of skull narrowing airway at nasopharynx. (**Figure 3**). Further, Computed tomography (CT) scan showed isodense, soft tissue lesion, in nasopharyngeal region. There were no enhancement, calcifications within the mass and no erosions of surrounding walls (**Figures 4**). A provisional diagnosis of Enlarged Adenoids were made and adenoidectomy was done under general anaesthesia after taking an informed and written consent. Specimen was sent for histopathology, the biopsy revealed adenoid hypertrophy. The patient was followed up after 3 and 9 months and remained symptoms free and nasal endoscopic examination was unremarkable (**Figures 5**).

Figure 1



Corresponding Author

Muhammad Moiz Ullah Khan²

Email: mmoizullah@hotmail.com

Affiliations:

Bahria University Medical and Dental College (BUMDC), Karachi^{1,2}

Department of ENT, Senior Professor¹

Department of ENT, Senior Registrar²

Submitted: May 30, 2024,

Revised: August 16, 2024

Accepted: August 16, 2024

Figure 2

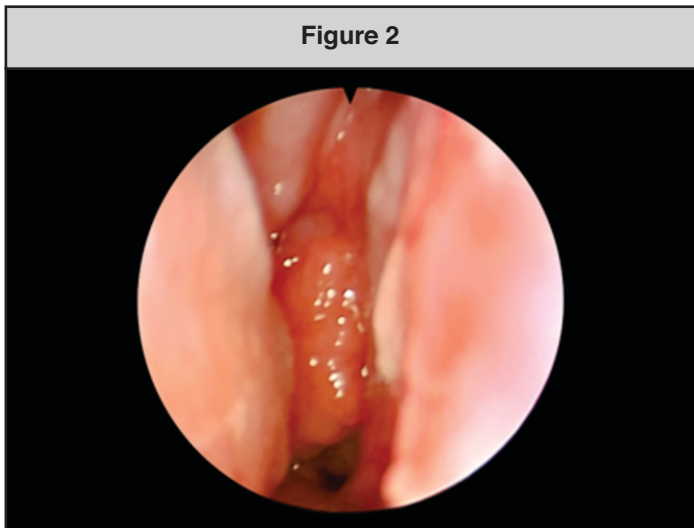


Figure 3

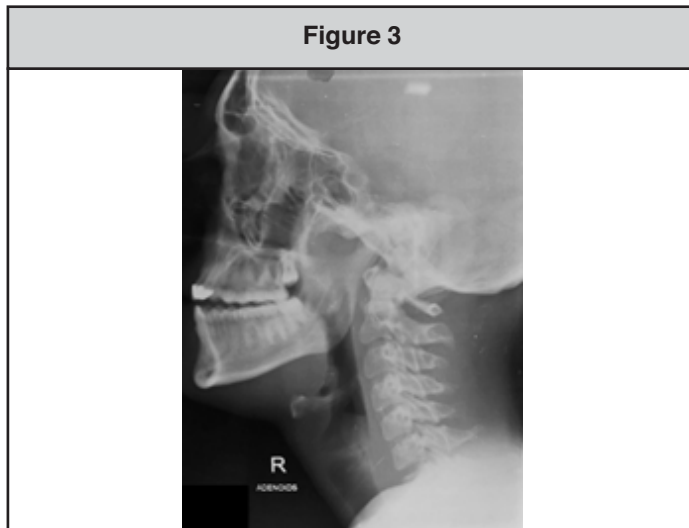


Figure 4

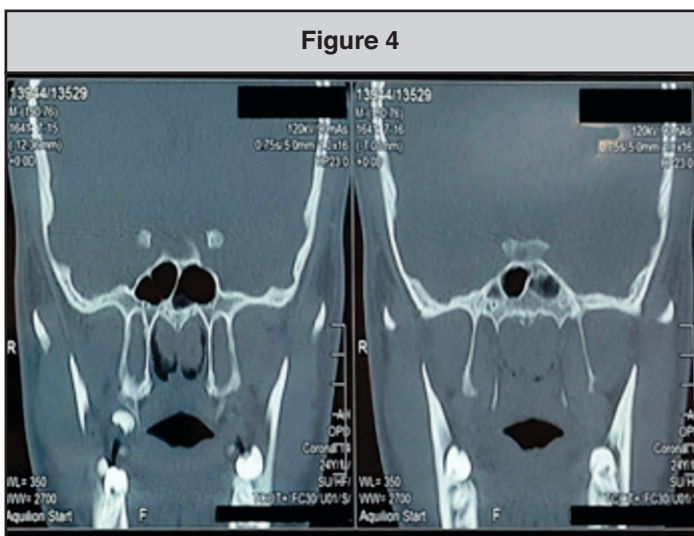
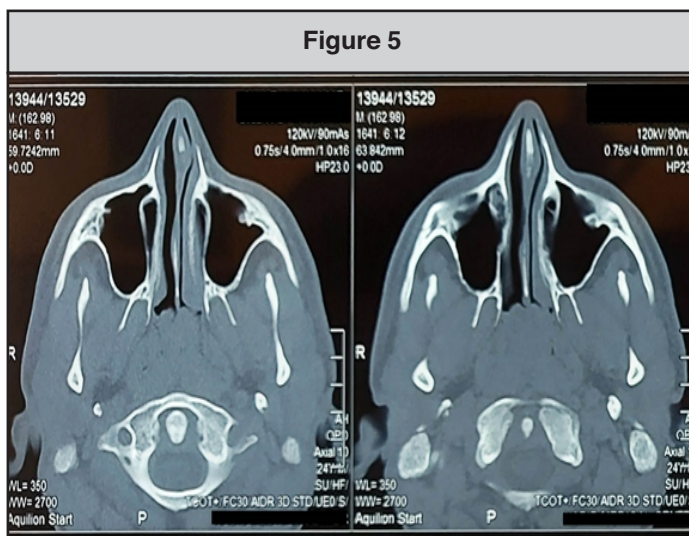


Figure 5



DISCUSSION

In children, adenoid hypertrophy is a usual complain but In adults on the other hand nasal obstruction is mostly due to deviated nasal septum, turbinate hypertrophy and nasal polyps⁶. Adenoid tissue atrophy occurs later in childhood, but it can persist into adulthood and become a significant cause of nasal obstruction⁷. Adult adenoid isn't uncommon but is frequently ignored. The cause of adenoid hypertrophy isn't known yet still come suggest, reactivation or persistence of childhood adenoids in adults leads to chronic inflammation⁸.

Excision and a histopathological examination are required to rule out malignancy in adults with adenoid hypertrophy that causes nasal obstruction. Frequency of Adenoids in adults in studies conducted by Alexey Surov et al, Zeliha Kapusuz et al, Muhammad Ahmed Khan et al⁹ in which it was 18%, 26%, 2.5% and 4.31% respectively. Most of adult patients presents between 17 to 25-year age group and males were affected more as compare to females which may be due to more exposure to outdoor pollutants and nasal obstruction was the symptom of presentation¹⁰.

Adenoids can not be diagnosed on clinical examination alone. They may be detected by CT scan but need confirmation by histopathology. There is no role of medical therapy in treatment of adenoid hypertrophy but they may be treated by surgical excision, with minimal risk of recurrence. They carry excellent prognosis after complete excision.

CONCLUSION

Even though adults rarely have adenoid hypertrophy, otorhinolaryngologists should not miss the diagnosis by properly examining the nasopharynx in cases of nasal obstruction. Adenoidectomy has a similar effect on adults, alleviating symptoms.

Conflict of Interest: Authors declared no conflict of interest.

Source of Funding: Nil

Authors' Contributions: **Udaipurwala IH:** Designed the study, collected and analyzed clinical data, and wrote the initial draft of the manuscript. **Khan MMU:** Conducted the adenoidectomy, reviewed the histopathology, and helped revise the manuscript.

REFERENCES

1. Rout MR, Mohanty D, Vijaylaxmi Y, Bobba K, Metta C. Adenoid hypertrophy in adults: a case series. *Indian J Otolaryngol Head Neck Surg.* 2013;65(3):269-74.
2. Pereira L, Monyror J, Almeida FT, Almeida FR, Guerra E, Flores-Mir C, et al. Prevalence of adenoid hypertrophy: a systematic review and meta-analysis. *Sleep Med Rev.* 2018;38:101-12.
3. Althobaiti T, Hadaidi WA, Alghamdi AS, Alghashmari KF, Hadaidi AA, Abd-Elrahman TM. Adenoid hypertrophy in adults: causes and precipitating factors. *Int J Med Dev Countries.* 2020;4(11):1792.

4. Khafagy YW, Mokbel KM. Choanal adenoid in adults with persistent nasal symptoms: endoscopic management to avoid misdiagnosis and unsuccessful surgeries. *Eur Arch Otorhinolaryngol.* 2011;268(11):1589-92.
5. Shetty S, Aroor R, Bhandary SK, Bhat VS, Saldanha M, Alva S. Adult adenoid hypertrophy, is it persistent childhood adenoid hypertrophy? *Med J Dr DY Patil Uni.* 2016;9(2):216.
6. Ozsen M, Saraydaroglu O, Yirmibes S, Coskun HH. Lesions that mimic malignant tumors in nasopharyngeal biopsies: Case series of 10 years. *Tumori J.* 2022;108(2): 119-24.
7. Saeed M, Saeed S. Adenoids in adults. *APMC.* 2021;15(2):157-61.
8. Kamel RH, Ishak EA. Enlarged adenoid and adenoidectomy in adults: endoscopic approach and histopathological study. *J Laryngol Otol.* 1990;104(12): 965-7.
9. Khan MA, Nawaz FUH, Hakim A, Khan M. Frequency of adenoid hypertrophy among adult patients with nasal obstruction. *J Postgrad Med Inst.* 2018;32(3):262-5.
10. Shastry A, Malali R, Joy L, Archana P, Viswanatha B. Adenoid hypertrophy in adults: a prospective study. *Sch J Otolaryngol.* 2020;5(1):447-50.

How to cite: Udaipurwala IH, Khan MMU. Enlarged Adenoid in Adult Mimicking Nasopharyngeal Growth. *Pak J Med Dent Sci.* 2024;1(1):27-29